

Does the accuracy of duplex scanning in diabetic patients with critical limb ischemia agree more frequently with arteriography when performed at vascular “dedicated” or “nondedicated” facilities?

Authors: Ezio Faglia MD¹, Giacomo Clerici MD¹, Sergio Losa MD², Maurizio Caminiti MD, Alessandra Baudo, MD², Alberto Morabito PhD³

The Journal of Diabetic Foot Complications, 2011; Volume 3, Issue 3, No. 1, Pages 43-49 © All rights reserved.

Abstract:

Aim: To verify the agreement between arteriography and duplex scanning performed in vascular laboratories with or without expertise of their operators in duplex scanning study in diabetic patients with critical limb ischemia (CLI).

Methods: All diabetic patients referred to our Diabetic Foot Centre because of CLI according to TASC II parameters were evaluated with duplex scanning. If the duplex scanning was already available the results were recorded. If the duplex scanning had not previously been performed, it was carried out by experienced vascular surgeons of our Institute. In all patients a digital subtraction arteriography was carried out and diagnostic accuracy between duplex scan and arteriography was evaluated.

Results: During 2010, 344 diabetic patients were admitted because of CLI in 360 limbs, 268 (74.4%: group A) with and 92 (25.6%: group B) without duplex. No significant difference was found between the two groups regarding distribution of stenoses and occlusions in the arterial segments. No significant difference (chi-square = 3.50, $p = 0.062$) was found regarding the examination of the femoral/popliteal axis. The diagnostic accuracy pertaining to the examination of the infrapopliteal arteries was significantly higher in group B (chi-square = 21.2, $p < 0.001$).

Conclusions: In order to obtain a good consistency with arteriographic images of infrapopliteal arteries, the duplex scanning in diabetic patients with CLI should be performed by operators with expertise in diabetic occlusive arterial disease.

Key words: diabetic foot, critical limb ischemia, duplex scanning, arteriography

Abbreviations:

PAD: peripheral arterial disease - CLI: critical limb ischemia - TASC II: TransAtlantic Inter-Society Consensus 2007- TcPO₂: transcutaneous oxygen tension

Corresponding author:

G. Clerici
Diabetic Foot Centre
IRCCS MultiMedica
Via Milanese 300 20099 Sesto San Giovanni (Milan), Italy
Phone: 0039-02-24209464 | Fax: 0039-02-24209085
Email: giacomo.clerici@multimedica.it
Website: <http://www.diabeticfoot.it>

1. Diabetology Centre - Diabetic Foot Centre - IRCCS MultiMedica, Sesto San Giovanni (Milan), Italy

2. Vascular Surgery Unit - IRCCS MultiMedica, Sesto San Giovanni (Milan), Italy

3. Medical Statistics Unit - University of Milan, Italy

Introduction

The duplex scan has been proven to be a reliable non-invasive diagnostic tool¹ and its accuracy was confirmed by many studies in the general population with digital subtraction angiography².

In diabetic patients, occlusive peripheral arterial disease presents some morphologic peculiarities: obstructions are usually distal, calcific, and more prevalent than stenoses^{3,4}. Such a morphological picture is particularly evident in diabetic patients with critical limb ischemia (CLI)⁵.

In our diagnostic protocol, the duplex scanning is carried out by vascular surgeons of our hospital in order to assess noninvasively the morphological alterations of the occlusive

disease and also to provide our endovascular radiologist with useful indications of whether to perform an antegrade ipsilateral, contralateral or brachial approach⁶. In our experience we found a great difference on results from duplex scanning compared to those from arteriography, especially when the duplex examination was not performed in our hospital by skilled vascular surgeons.

Therefore, we designed this study in order to compare the diagnostic agreement between arteriography and duplex ultrasound scanning performed either in non specialized centres (*Group A*) or carried out by vascular surgeons of our hospital (*Group B*), who have expertise in diabetic patients with critical limb ischemia.

Patients and Methods

Protocol: All diabetic patients referred to our Diabetic Foot Centre for foot lesions or for rest pain were assessed for the presence of CLI with the TransAtlantic Inter-Society Consensus (*TASC II*) criteria¹¹. CLI was detected if transcutaneous oxygen tension (TcPO₂ - TCMTM3, Radiometer GMBH, Copenhagen, Denmark) at the dorsum of the foot was < 30 mmHg and ankle pressure was < 70 mmHg when measurable (no patent or non-compressible foot arteries at the ankle level because of medial calcifications) with a continuous wave (CW) Doppler instrument (*DIADOP 50, Mediland s.r.l. Varedo, Milan, Italy*).

In all patients with CLI duplex scanning was performed and an arteriography and revascularization (*when possible*) were carried out. In case a duplex scanning had not been previously performed by the referring institution, the procedure was then carried out by vascular surgeons of our Institute (*group B*). The duplex study was performed in the noninvasive vascular laboratory of the Vascular Surgery Unit of our

Institute, using an Acuson Sequoia 512 ultrasound machine (*Acuson Corporation, 1220 Charleston Road, Mountain View CA*). The lower limb arterial axis was examined along its length, Duplex signals were traced distally to under the malleolus, when possible. In all patients with CLI a digital subtraction arteriography was carried out. Digital subtraction arteriograms were performed by means of a biplanar method using an antegrade or contralateral trans-femoral or brachial approach.

For both, duplex and arteriography results the information was derived by printed results of the case history, using the definition of "stenosis" and "occlusion".

Of the duplex scanning and the angiographic study, we considered for the statistical analysis in the ischemic limb the common plus superficial femoral arterial segments, the popliteal artery, the anterior tibial artery, the posterior tibial artery,

the anterior tibial artery, the posterior tibial artery, and the peroneal artery. The iliac arteries were characterized in a very few duplex studies in group A: therefore a comparison between these arterial segments was not carried out. Peak systolic velocity was reported in only 11 cases of group A and, therefore, this parameter was not compared between the two groups.

Statistical analysis: We reported the descriptive statistics as average values and standard deviation of continuous variables, and as percentages of the discrete variables. The difference between detected variables was evaluated by Student's t-test for continuous variables, or chi square test for discrete variables. The 95% level has been adopted

to ascertain the confidence intervals and 5% level has been considered to test the null hypothesis. We have compared the diagnostic accuracy level of Doppler examination with that of the angiographic study: we assessed the consistency between the two procedures when duplex examination was carried out either in "dedicated diabetic foot centers" or in centers without specific expertise. Then, we carried out an indirect comparison resorting to chi square test in the two groups of patients.

The Stata 10.0 software package (Statistics/Data Analysis, Stata Corporation, 4905 Lakeway Drive, College Station, Texas 77845 USA, 800-STAT-PC) was used.

Results

During 2010, 344 diabetic patients were admitted to our foot centre because of CLI in 360 limbs according to the TASC 2007 parameters¹¹. In 268 (74.4%) patients (*group A*) a Duplex scanning had previously been performed in other centres; in the remaining 92 (25.6%) patients (*group B*) who had not previously undergone a duplex study, the procedure was carried out in our Institute by experienced vascular surgeons. No significant difference was found between the two groups regarding the recorded demographics and clinical characteristics of the two patient groups.

Some results from duplex examination in group A were missing: the iliac trunk was not evaluated in 3 patients, the popliteal artery in 1 patient, the anterior tibial artery in 7, the posterior tibial artery in 9, and the peroneal artery was not evaluated in 119 patients. In group B

patients the peroneal artery was not evaluated in 3 patients. In group A the iliac arteries were characterized in a very few tests and a comparison between these arterial segments was not carried out. Similarly, the determination of peak systolic velocity was not routinely performed and therefore no such comparisons between groups could be made.

All patients underwent arteriography in our center. Obstructions > 50% of vessel diameter

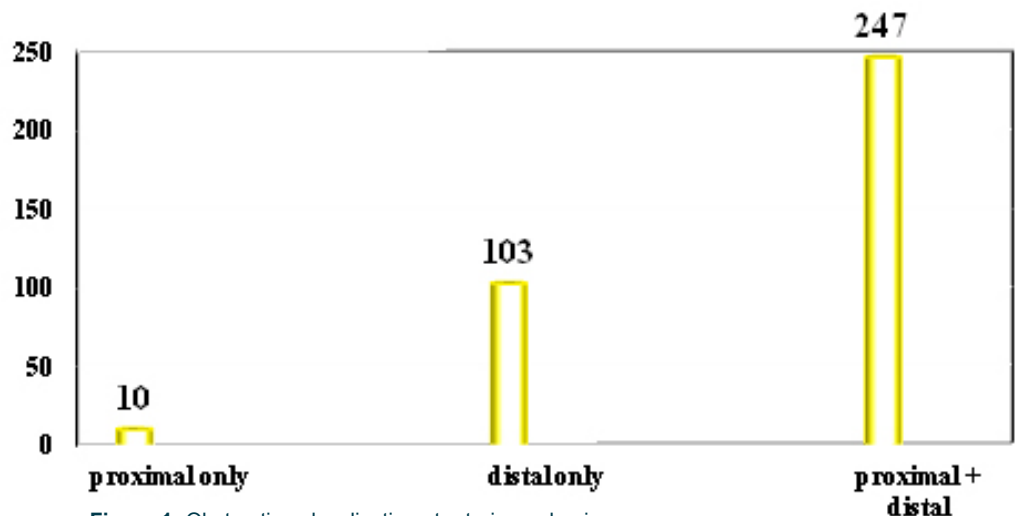


Figure 1: Obstructions localization at arteriography in proximal only, distal only or both (n = 360)

were located exclusively in the proximal (femoral/popliteal) axis in 10 limbs (2.8%), exclusively in the distal (infrapopliteal) axis in 103 (28.6%) limbs, and in both proximal and distal axis in 247 limbs (68.6%). **Figure 1** shows the localization of the obstruction in the ischemic limb.

In Group A the accuracy of the duplex scan performed in proximal arteries (femoral and popliteal) was not significantly different from that carried out in patients of group B: $\chi^2 = 3.50$, $p = 0.062$.

However, the difference between the accuracy of infrapopliteal artery (anterior tibial, posterior tibial, and peroneal) duplex scanning performed in Group A and that one performed in group B was highly significant: $\chi^2 = 21.2$, $p < 0.001$.

Table 1 reports the percentage of stenoses and occlusions of ischemic limb in group A and B.

Table 2 reports the matched results in each evaluated artery of the ischemic limb in group A and B.

	group A		group B		
arteries	stenoses	occlusions	stenoses	occlusions	
femoral	87 (32.5%)	80 (30.0%)	30 (32.6%)	28 (30.4%)	1.00
popliteal	73 (27.2%)	52 (19.4 (%))	25 (27.2%)	18 (19.6%)	1.00
anterior tibial	62 (23.1%)	176 (65.7%)	23 (25.0%)	58 (63.0%)	0.666
posterior tibial	30 (11.2%)	203 (75.7(%))	11 (12.0%)	70 (76.1%)	0.850
peroneal	59 (22.0%)	105 (39.2%)	22 (23.9%)	35 (38.0%)	0.751

Table 1: Stenoses and occlusions acquired from arteriography analysis in the ischemic limb in group A (N = 268) and group B (N = 92)

arteries	group A	group B	p
femoral	230 (85.8%)	88 (95.6%)	0.075
popliteal	152 (77.9%)	52 (85.3%)	0.252
anterior tibial	105 (53.8%)	49 (80.3%)	< 0.001
posterior tibial	97 (49.7%)	46 (75.4%)	< 0.001
peroneal	44 (22.6%)	35 (57.4%)	< 0.001

Table 2: Correspondence in detecting arteries between duplex scanning and arteriography reports in group A (N = 268) and group B (N = 92)

Discussion

This is a retrospective study: the analysis of the concordance between duplex and arteriography was performed during the evaluation of the data of a prospective study of feasibility of PTA in diabetic patients with CLI. The data were collected using the printed reports enclosed in the case history of the patients. This prevented us from doing a methodologically robust comparison (ie: arteriography results compared by blinded observers, etc). On the other hand, duplex accuracy was evaluated in a real (*Italian*) world.

Duplex scanning is a safe, inexpensive and accurate diagnostic tool to map the locations and to describe the severity of occlusive arterial disease in the lower limbs⁷. This is true for non diabetic patients, but is it also true for the diabetic patients? For diabetic patients the American

Diabetes Association, in a Position Statement dated December 2003, indicated that duplex scanning was a potential diagnostic tool in patients eligible for revascularization, together with magnetic resonance arteriography⁸. However, in our opinion, it is not clear whether this procedure might be useful also in diabetic patients with CLI: only a few studies have evaluated the feasibility and accuracy of such an exam in these patients^{9,10}. The January 2007 edition of the Inter-Society Consensus (*TASC II*) defined duplex scanning as a procedure with a “widespread availability, without relative risk and complications, without contraindications”. However, also some weaknesses are recognized, as duplex scanning is a very “operator-dependent technique”, and because “calcified segments are difficult to assess”¹¹. We strongly agree with this statement. In fact, in our

clinical practice we noticed a consistent discrepancy between results from duplex analyses performed elsewhere and arteriographic pictures. This was particularly evident in the case of infrapopliteal arterial examinations. Such a discrepancy was less evident when examinations were performed by vascular surgeons of our Institute, who are skilled in occlusive arterial disease in diabetic patients. It is important to clarify how in the USA, the execution of a duplex scan is conducted by a specialised non-physician operator, and a physician is required for the interpretation of the test. In Italy, both the execution and interpretation is carried out by a physician, usually a vascular surgeon.

This prompted us to perform this analysis with the aim of comparing the accuracy of examinations performed in skilled facilities with those obtained in non-skilled ones, rather than simply comparing the accuracy of the procedure itself. The results of the study have fully confirmed our suspicions of the inaccuracy in the tests performed in general laboratories, without expertise in occlusive peripheral arterial disease of diabetic patients.

There is a great consensus in literature on the optimal accuracy of duplex scanning in proximal arteries^{13,14}. In our study the inconsistency between the accuracy of proximal arteries examination performed by skilled or non-skilled operators was not dramatic. However, if one considers that duplex scanning guide the interventionist's choice of site's puncture (*ipsilateral, contralateral or brachial puncture*), an error of almost 14% may be deemed considerable. This is an important tool for the endovascular operators. For this reason, we believe that the results obtained from a duplex scan performed in general facilities cannot be considered as "optimal".

Instead, there is currently a lack of consensus on the accuracy of infrainguinal arterial examination even in the general population. In some studies the accuracy appeared to

be optimal also in the infrainguinal arteries, while in others it was not satisfactory and definitely lower than that obtained in the proximal arterial examination¹⁵⁻²⁰. In our data the accuracy of infrapopliteal artery examination performed in a general laboratory significantly worsened. In particular, the evaluation of the peroneal artery was missing in most cases. Nonetheless, when such evaluation was performed the accuracy was very poor. In our experience, we revascularize by peripheral transluminal angioplasty (PTA) or bypass graft surgery (BPG) just in this artery for a reasonable percentage of our CLI diabetic patients where this is the only patent artery below the knee²¹.

Our data clearly has shown that in diabetic patients the accuracy of infrapopliteal examination was dramatically lower when duplex scanning was performed by non experienced operators as compared to that obtained from studies performed by operators with expertise. Moreover, the accuracy was even lower in the case of peroneal artery examination²².

Therefore, we fully agree with the conclusions of the recent study of Moneta stating that "physicians interpreting vascular laboratory studies should be part of structures that can offer proper training and credentialing". We believe this is particularly true when such tests are performed in diabetic patients.²³

The use of duplex scanning as an alternative to arteriography in the decision making regarding revascularization has been matter of debate.²⁴⁻²⁸ Our data has shown that in diabetic patients candidates for revascularization in infrapopliteal arteries, especially in the peroneal artery, duplex scanning was not adequate to guide decision making pertaining to surgical revascularization²⁹. This also held true when the exam was performed by skilled physicians with expertise in diabetic peripheral arterial disease.

Conclusion

In order to obtain a good consistency with arteriographic images of the femoral artery, duplex scanning in diabetic patients with CLI must be performed by a highly skilled and experienced physician (Italy) or vascular technologist (USA). This is an important tool for the endovascular operators. The unsatisfactory accuracy of the duplex also performed by experienced physicians in the infrapopliteal axis was not adequate

to guide decision making in surgical revascularization. If, in the future, the vascular ultrasonography instruments will be of higher-quality and operators will be well-trained, then duplex scanning may represent an alternative to conventional arteriography even in diabetic patients.

Competing interests: None declared.

References

1. Ramaswami G, Al-Kutoubi A, Nicolaidis AN, Dhanjil S, Griffin M, Belcaro G, Coen LD. The role of duplex scanning in the diagnosis of lower limb arterial disease. *Ann Vasc Surg* 1999; 13:494-500.
2. Collins R, Burch J, Cranny G, Aguiar-Ibáñez R, Craig D, Wright K, Berry E, Gough M, Kleijnen J, Westwood M. Duplex ultrasonography, magnetic resonance angiography, and computed tomography angiography for diagnosis and assessment of symptomatic, lower limb peripheral arterial disease: systematic review. *BMJ* 2007;16:1257-66.
3. Jude EB, Oyibo SO, Chalmers N, Boulton AJ. Peripheral arterial disease in diabetic and nondiabetic patients. A comparison of severity and outcome. *Diabetes Care* 2001; 24:1433-7.
4. van der Feen C, Neijens FS, Kanters SD, Mali WP, Stolk RP, Banga JD. Angiographic distribution of lower extremity atherosclerosis in patients with and without diabetes. *Diabet Med* 2002;19:366-70.
5. Kansal NK. Handman Clinical features and diagnosis of macrovascular disease. In: Veves A, Giurini JM, LoGerfo FW eds *The Diabetic Foot*, Humana Press 2002, pages 113-125
6. Faglia E, Dalla Paola L, Clerici G, Clerissi J, Graziani L, Fusaro M, Gabrielli L, Losa S, Stella A, Gargiulo M, Mantero M, Caminiti M, Ninkovic S, Curci V, Morabito A. Peripheral angioplasty as the first-choice revascularization procedure in diabetic patients with critical limb ischemia: prospective study of 993 consecutive patients hospitalized and followed between 1999 and 2003. *Eur J Vasc Endovasc Surg* 2005;29:620-7.
7. Bradbury AW, Adam DJ. Diagnosis of peripheral arterial disease of the lower limb. *BMJ* 2007;334:1229-30.
8. American Diabetes Association Peripheral Arterial Disease in People with Diabetes. *Diabetes Care* 2003;26:333-41
9. Ascher E, Marks NA, Hingorani AP, Schutzer RW, Mutyala M. Duplex-guided endovascular treatment for occlusive and stenotic lesions of the femoral-popliteal arterial segment: a comparative study in the first 253 cases. *J Vasc Surg* 2006, 6:1230-7.
10. Koelemay MJ, Legemate DA, Reekers JA, Koedam NA, Balm R, Jacobs MJ. Interobserver variation in interpretation of arteriography and management of severe lower leg arterial disease. *Eur J Vasc Endovasc Surg* 2001;21:417-22.
11. Norgren L, Hiatt WR, Dormandy JA, Nehler MR, Harris KA, Fowkes FG; TASC II Working Group. Inter-Society Consensus for the Management of Peripheral Arterial Disease (TASC II). *J Vasc Surg* 2007;45 Suppl S:S5-67.
12. Faglia E, Clerici G, Clerissi J, Mantero M, Caminiti M, Quarantiello A, Curci V, Lupattelli T, Morabito A. When is a technically successful peripheral angioplasty effective in preventing above-the-ankle amputation in diabetic patients with critical limb ischaemia ? *Diabet Med* 2007;24:823-9.
13. Moneta GL, Yeager RA, Antonovic R, Hall LD, Caster JD, Cummings CA, Porter JM. Accuracy of lower extremity arterial duplex mapping. *J Vasc Surg* 1992;15:275-83.
14. Koelemay MJ, den Hartog D, Prins MH, Kromhout JG, Legemate DA, Jacobs MJ. Diagnosis of arterial disease of the lower extremities with duplex ultrasonography. *Br J Surg* 1996; 83:404-9.
15. Favaretto E, Pili C, Amato A, Conti E, Losinno F, Rossi C, Faccioli L, Palareti G. Analysis of agreement between Duplex ultrasound scanning and arteriography in patients with lower limb artery disease. *J Cardiovasc Med* 2007; 8:337-41.

16. Larch E, Minar E, Ahmadi R, Schnürer G, Schneider B, Stümpflen A, Ehringer H. Value of color duplex sonography for evaluation of tibioperoneal arteries in patients with femoropopliteal obstruction: a prospective comparison with anterograde intraarterial digital subtraction angiography. *J Vasc Surg* 1997; 25:629-36.
17. Aly S, Jenkins MP, Zaidi FH, Coleridge Smith PD, Bishop CC. Duplex scanning and effect of multisegmental arterial disease on its accuracy in lower limb arteries. *Eur J Vasc Endovasc Surg* 1998;16:345-9.
18. Sensier Y, Fishwick G, Owen R, Pemberton M, Bell PR, London NJ. A comparison between colour duplex ultrasonography and arteriography for imaging infrapopliteal arterial lesions. *Eur J Vasc Endovasc Surg* 1998;15:44-50.
19. Karacagil S, Löfberg AM, Granbo A, Lörelus LE, Bergqvist D. Value of duplex scanning in evaluation of crural and foot arteries in limbs with severe lower limb ischaemia--a prospective comparison with angiography. *Eur J Vasc Endovasc Surg* 1996;12:300-3.
20. Grassbaugh JA, Nelson PR, Rzucidlo EM, Schermerhorn ML, Fillinger MF, Powell RJ, Zwolak RM, Cronenwett JL, Walsh DB. Blinded comparison of preoperative duplex ultrasound scanning and contrast arteriography for planning revascularization at the level of the tibia *J Vasc Surg* 2003;37:1186-90.
21. Abularrage CJ, Conrad MF, Hackney LA, Paruchuri V, Crawford RS, Kwolek CJ, LaMuraglia GM, Cambria RP. Long-term outcomes of diabetic patients undergoing endovascular infrainguinal interventions. *J Vasc Surg*. 2010 Aug;52(2):314-22.e1-4. Epub 2010 Jun 29.
22. Dosluoglu HH, Cherr GS, Lall P, Harris LM, Dryjski ML. Peroneal artery-only runoff following endovascular revascularizations is effective for limb salvage in patients with tissue loss. *J Vasc Surg*. 2008 Jul;48(1):137-43. Epub 2008 May 23.
23. Moneta GL, Zierler RE, Zierler BK. Training and credentialing in vascular laboratory diagnosis. *Semin Vasc Surg* 2006;19:205-9.
24. Ascher E, Markevich N, Schutzer RW, Kallakuri S, Hou A, Nahata S, Yorkovich W, Jacob T, Hingorani AP. Duplex arteriography prior to femoral-popliteal reconstruction in claudicants: a proposal for a new shortened protocol. *Ann Vasc Surg* 2004;18:544-51.
25. Katsamouris AN, Giannoukas AD, Tsetis D, Kostas T, Petinarakis I, Gourtsoyiannis N. Can ultrasound replace arteriography in the management of chronic arterial occlusive disease of the lower limb? *Eur J Vasc Endovasc Surg* 2001;21:155-9.
26. Mazzariol F, Ascher E, Salles-Cunha SX, Gade P, Hingorani A. Values and limitations of duplex ultrasonography as the sole imaging method of preoperative evaluation for popliteal and infrapopliteal bypasses. *Ann Vasc Surg* 1999;13:1-10.
27. Avenarius JK, Breek JC, Lampmann LE, van Berge Hengouwen DP, Hamming JF. The additional value of angiography after colour-coded duplex on decision making in patients with critical limb ischaemia. A prospective study. *Eur J Vasc Endovasc Surg* 2002;23:393-7.
28. Luján S, Criado E, Puras E, Izquierdo LM. Duplex scanning or arteriography for preoperative planning of lower limb revascularisation. *Eur J Vasc Endovasc Surg* 2002; 24:31-6.
29. Hingorani AP, Ascher E, Marks N. Duplex arteriography for lower extremity revascularization. *Perspect Vasc Surg Endovasc Ther* 2007;19:6-20.